
Advanced chemical peels: Phenol-croton oil peel



Carlos G. Wambier, MD, PhD,^a Kachiu C. Lee, MD, MPH,^b Seaver L. Soon, MD,^c J. Barton Sterling, MD,^d Peter P. Rullan, MD,^e Marina Landau, MD,^f and Harold J. Brody, MD,^g for the International Peeling Society
New Haven, Connecticut; Providence, Rhode Island; San Diego, California; Spring Lake, New Jersey; Holon, Israel; and Atlanta, Georgia.

Learning objectives

After completing this learning activity, participants should be able to describe the effect of a light, medium, and heavy deep peel (Hetter formula) and where to use each formulation; explain the side effect profile of deep peels; discuss special chemical peel techniques such as CROSS, blebpeeling, and earlobe repair; and discuss the principles for performing a combination, medium, and deep peel on different cosmetic units of the face when indicated.

Disclosures

Editors

The editors involved with this CME activity and all content validation/peer reviewers of the journal-based CME activity have reported no relevant financial relationships with commercial interest(s).

Authors

The authors involved with this journal-based CME activity have reported no relevant financial relationships with commercial interest(s).

Planners

The planners involved with this journal-based CME activity have reported no relevant financial relationships with commercial interest(s). The editorial and education staff involved with this journal-based CME activity have reported no relevant financial relationships with commercial interest(s).

Once considered the standard for deep facial resurfacing, the classical Baker-Gordon phenol-croton oil peel has largely been replaced by formulas with lower concentrations of phenol and croton oil. The improved safety profile of deep peels has ushered in a new era in chemical peeling. Wrinkles can be improved and skin can be tightened with more subtle and natural results. No longer does a deep peel denote “alabaster white” facial depigmentation with complete effacement of wrinkles. Gregory Hetter’s research showed that the strength and corresponding depth of penetration of the phenol-croton oil peel can be modified by varying the concentration of croton oil. This second article in this continuing medical education series focuses on the main historical, scientific, and procedural considerations in phenol-croton oil peels. (*J Am Acad Dermatol* 2019;81:327-36.)

Key words: acne scars; Baker peel; Baker-Gordon peel; chemabrasion; chemical peeling; chemexfoliation; croton oil; *Croton tiglium*; deep chemical peel; deep peeling; Hetter peel; phenol; phenol-croton oil peel; photoaging; photorejuvenation; procedural dermatology.

BACKGROUND

From the Department of Dermatology,^a Yale University School of Medicine, New Haven; Department of Dermatology,^b Warren Alpert School of Medicine, Brown University, Providence; Division of Dermatology,^c Scripps Clinic, and the Department of Dermatology,^e University of California San Diego; Jersey Shore University Medical Center,^d Spring Lake; Dermatology Clinic,^f Wolfson Medical Center, Holon; and the Department of Dermatology,^g Emory University School of Medicine, Atlanta.

Funding sources: None.

Conflicts of interest: None disclosed.

Accepted for publication November 21, 2018.

Reprint requests: Kachiu C. Lee, MD, MPH, 593 Eddy St, APC 10, Providence, RI 02903. E-mail: kachiu@gmail.com.

0190-9622

Published by Elsevier on behalf of the American Academy of Dermatology, Inc.

<https://doi.org/10.1016/j.jaad.2018.11.060>

Date of release: August 2019

Expiration date: August 2022



Scanning this QR code will direct you to the CME quiz in the American Academy of Dermatology’s (AAD) online learning center where after taking the quiz and successfully passing it, you may claim 1 AMA PRA Category 1 credit. NOTE: You must have an AAD account and be signed in on your device in order to be directed to the CME quiz. If you do not have an AAD account, you will need to create one. To create an AAD account: go to the AAD’s website: www.aad.org.

Key points

- Brown described a phenol-croton oil formula in 1959
- Baker-Gordon's formula (2.1% croton oil) was the standard from 1962 to 2000
- Hetter's formulas ($\leq 1.6\%$ croton oil) became the standard after 2000
- Croton oil is the active ingredient

Croton oil is obtained from the seeds of *Croton tiglium*, a vegetal matrix of phorbol esters. These compounds display a broad range of biologic activities over several proteins/enzymes.¹ The activation of protein kinase C causes extreme inflammatory and promoter effects.² Medicinal applications dated back to the 1800s,³ and lay peelers mixed it with other ingredients including phenol in the 1900s.⁴ Phenol causes epidermal and superficial dermal coagulation but is capable of conveying phorbols to the dermis.⁵

In 1959, Brown's patent documented a formula containing phenol and croton oil.⁶ By 1960, other plastic surgeons practiced with formulas derived from lay peelers with the assumption that phenol, and not croton oil, was the active ingredient.⁷⁻⁹ Baker first published a formula containing 1.2% croton oil in 47.5% phenol in a medical journal in 1961.⁸ One year later, Baker reduced the volume of the formula but maintained the original drops of croton oil.¹⁰ The croton oil concentration was thus increased to 2.1% (Table I), increasing the risks of scarring and persistent hypopigmentation.¹¹ This Baker-Gordon formula was widely adopted with a standard emulsifying agent, Septisol (Steris Corp, Mentor, OH), with 0.25% triclosan (formerly hexachlorophene) as the antibacterial agent and sorbitol (formerly glycerin) as the humectant. Trials to replace Septisol with another detergent without triclosan are ongoing.¹²

Hetter refuted that phenol was the active ingredient in 1996 and showed that croton oil is the active agent. With a series of 4 publications in 2000, Hetter outlined the rationale for referring to formulas by the percentage of croton oil and phenol (Tables II and III).^{4,11,13-16} Subsequently, others confirmed that wounding depth relates to croton oil concentration.^{17,18}

HISTOLOGY**Key points**

- Deep peels produce mid-reticular dermal injury with marked collagen formation and organization of elastic fibers

Table I. Baker's formulas of phenol-croton oil peels*

	Original formula (1961)	Classical formula (1962), Baker-Gordon's peel
Croton oil	1.2%	2.1%
Phenol	47.5%	49.3%
Croton oil	3 drops	3 drops
Phenol (88%)	5 mL	3 mL
Water	4 mL	2 mL
Septisol	5 drops	8 drops

Septisol is a trademark of Steris Corp (Mentor, OH).

*From Baker⁸ and Baker.¹⁰

- These changes persist for over a decade
- More strokes with peel agents increase wound depth

The most important histologic observation is a dense, dermal neocollagenesis zone (Fig 1) that increases until 16 weeks.¹⁹ Organized elastic fibers replace the elastosis.²⁰ Melanin granules decrease despite the presence of melanocytes.²¹⁻²⁶

Occlusion increases the depth of effects when compared with unoccluded skin.^{23,27,28} At 3 months of follow-up, the neocollagenesis zone measures 350 μm in occluded Baker-Gordon peels compared with 260 μm without occlusion. Despite deeper abrasion, CO₂ lasers form neocollagen bands from 150 to 200 μm .²⁹

Kligman et al²⁰ evaluated the long-term histologic effects of deep peels and found that changes persisted 15 to 20 years later. A wide band of healthy dermis is sharply demarcated from the deeper, sun-damaged dermis and consists of a parallel arrangement of collagen fibers and elastic fibers.²⁰

One pig study rank-ordered the depth of injury of different modalities and yielded the following results, from deepest to most superficial: a single pass of Baker-Gordon, 3 passes of CO₂ laser, dermabrasion, 1 pass of 35% trichloroacetic acid, and 1 pass of CO₂ laser.²²

Minipig experiments demonstrated no difference in the depth of necrosis and neutrophilic infiltrate in adhesive tape or ointment occlusion. Epithelization was faster with ointment than with tape and was slowest in unoccluded skin. Dermal effects were similar in wet and moist application, although less repigmentation was observed with wet application.³⁰

A pig study confirmed Hetter's clinical findings by showing that depth increases with croton oil concentration and the number of strokes.⁵ Unoccluded 20% to 80% phenol emulsions without croton oil produced light wounds, which took

Table II. Hetter's phenol-croton formulas, also known as the "heresy" formulas (1996)¹³

	Heavy	Medium	Light	Very light
Croton oil concentration*	1.1%	0.7%	0.35%	0.1%
Phenol concentration	33%	33%	33%	27.5%
Croton oil	3 drops	2 drops	1 drop	3mL of 0.35%
Phenol (88%)	4 mL	4 mL	4 mL	2 mL
Water	6 mL	6 mL	6 mL	5 mL
Septisol [†]	16 drops	16 drops	16 drops	0 drop
Suggested indications				
Wrinkle depth	Deep	Moderate	Mild	Very mild
Cosmetic areas	Perioral, nose	Forehead, cheeks	Periocular	Eyelids, neck

*Each drop of croton oil added to 4 mL of phenol 88%, followed by 6.0 mL of water and 0.5 mL of Septisol, results in 0.35% increments. An additional drop to the heavy formula creates a 1.4% croton oil formula.

[†]Septisol is a trademark of Steris Corp (Mentor, OH).

Table III. Hetter's phenol-croton oil standardized formulas containing 35% phenol (2000) in 10 mL¹³

	Very heavy	Heavy	Medium	Light	Very light
Croton oil concentration*	1.6%	1.2%	0.8%	0.4%	0.1%
Hetter's stock [†]	4 mL	3 mL	2 mL	1 mL	0.25 mL
Phenol (88%)	0 mL	1 mL	2 mL	3 mL	3.75 mL
Water	5.5 mL	5.5 mL	5.5 mL	5.5 mL	5.5 mL
Septisol [‡]	0.5 mL	0.5 mL	0.5 mL	0.5 mL	0.5 mL
Suggested indications					
Wrinkle depth	Very deep	Deep	Moderate	Mild	Very mild
Cosmetic areas	Perioral, chin	Perioral, nose	Forehead, cheeks	Periocular	Eyelids, neck

*Each mL of Hetter's stock or drop of croton oil results in 0.4% increments in croton oil in formulas containing a total of 10 mL.

[†]Hetter's stock solution (1 mL of croton oil mixed with 24 mL of phenol 88%) contains 4% croton oil in phenol. Each milliliter of the stock solution contains 0.04 mL of croton oil, equivalent to 1 drop of croton oil from a Delasco dropper, which produces ~25 drops/mL. Never use stock solution undiluted on patients.

[‡]Septisol is a trademark of Steris Corp (Mentor, OH).

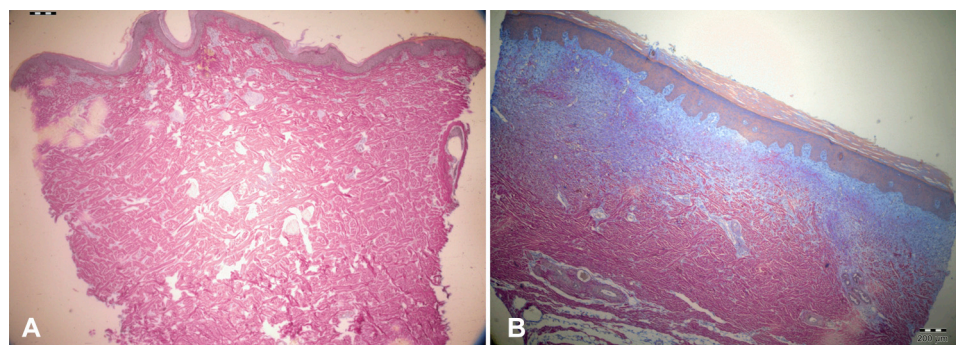


Fig 1. Evaluation of the neocollagenesis band in punch biopsy specimens obtained on postoperative day 21 in a pig study on phenol-croton oil peels. **A**, Septisol and water, negative control, shows mature collagen (type I collagen, red) throughout the full dermal thickness. **B**, Hetter's very heavy formula containing 1.6% croton oil in 35% phenol, positive control, shows a dense 400- to 1000- μ m band of new collagen (type III collagen, blue). Epidermal thickening is also observed. (Herovici stain; original magnification: $\times 20$. Photographs courtesy Justo AS, Lemes BM, Lipinski LC, Wambier CG, and Beltrame FL.)

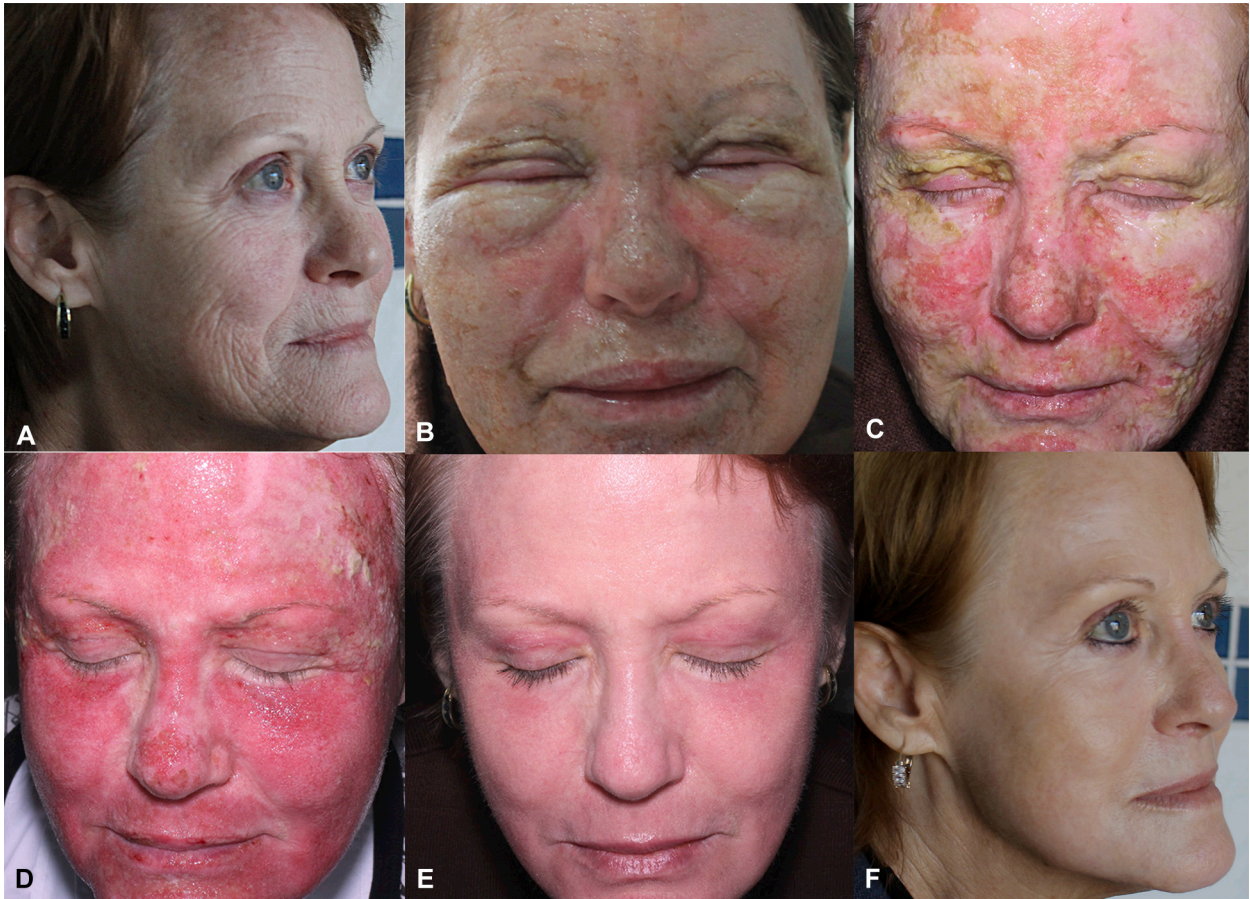

Fig 2. The expected evolution of a full-face peel with 1.6% croton oil in 35% phenol with petrolatum jelly occlusion. **A**, Baseline: Glogau classification of photoaging IV, deep rhytides. **B**, Postoperative day (POD) 1: edema, vesicles, and caramel exudate. **C**, POD 3: evidence of a purulent exudate. Edema is resolving. **D**, POD 6: no exudate. Gradual detachment of eschars. Fibrin forms continuously until reepithelization. **E**, POD 14: complete reepithelialization with erythema. **F**, Follow-up at 12 months: overall improvement of rhytides.

longer to heal in higher concentrations of phenol. Without Septisol, the peel is less deep. The same emulsions, with 0.2% or 2% croton oil, produced a dose-dependent clinically and histologically deeper burn, with intense inflammation and a prolonged healing period. When water is replaced by ethanol, simulating Fintsi's formula,³¹ the depth and inflammation are reduced, because ethanol cannot carry the active compounds present in croton oil as deeply into the skin as phenol.⁵

CLINICAL INDICATIONS FOR PHENOL-CROTON OIL

Key points

- Phenol-croton oil offers the ability to treat multiple degrees of photoaging by strength gradation
- Phenol-croton oil can be used on the face and the front of the neck

Deep peels (Fig 2) are traditionally indicated for the treatment of severe rhytides (Glogau classification of photoaging IV) and severe acne scars. The indications have broadened since Hetter's work on strength gradation, with new indications such as moderate photodamage (Glogau classification of photoaging III). Other indications may include treatment of xanthelasma, actinic keratosis,³² actinic cheilitis, and augmentation and eversion of the lips.³³

The clinical indications of deep chemical peels overlap with other resurfacing and surgical procedures, often with a cost-benefit profile³⁴ (Table IV) and clinical durability in favor of deep peels.^{20,21,23,24,29,35} Nonetheless, randomized comparative trials are needed to better define the clinical and the histologic outcomes of deep peels relative to other approaches to resurfacing currently in use, such as fractional ablative and nonablative lasers, fractional ablative radiofrequency, and microneedling.

Table IV. Resurfacing procedures*

Costs [†]	Efficacy	Reepithelization period	Complete healing period
Fully ablative CO ₂ laser	Phenol-croton oil peels	Phenol-croton oil peels	Fully ablative CO ₂ laser
AFL	Fully ablative CO ₂ laser	Fully ablative CO ₂ laser	Phenol-croton oil peels
NAFL	Dermabrasion	Dermabrasion	Dermabrasion
AFRF	AFL	AFL	AFL
Microneedling	Medium-depth peels	Medium-depth peels	Medium-depth peels
Dermabrasion	Microneedling	AFRF	AFRF
Phenol-croton oil peels	AFRF	NAFL	NAFL
Medium-depth peels	NAFL	Microneedling	Microneedling

AFL, Ablative fractional laser; AFRF, ablative fractional radiofrequency; NAFL, nonablative fractional laser.

Adapted from Wambier et al.³⁴

*Estimated ranking in decreasing vertical order of perceived costs, efficacy, reepithelization period (downtime of a procedure), and complete healing period for the results of a single procedure. Results of a survey of 14 experts in resurfacing techniques. The ideal procedure would have maximum efficacy, with minimal costs, reepithelization period, and complete healing period.

[†]Includes consumables, equipment, maintenance, energy, equipment insurance, office space, staff, and labor hours.

One randomized comparative trial showed superiority of unoccluded classic Baker's peel over pulsed CO₂ laser in the treatment of upper lip wrinkles.³⁶ Most split-face studies^{37,38} failed to perform side randomization, which is a methodological flaw because the left side usually suffers more intense sun damage in drivers.⁹ A small, nonrandomized prospective split-face comparative study between Baker-Gordon's formula and medium Hetter's formula concluded that outcomes were similar. Baker-Gordon's formula, however, was associated with greater adverse events, such as postinflammatory hyperpigmentation.³⁷ Another small, nonrandomized split-face study between unoccluded Baker-Gordon's formula and 2 passes of CO₂ laser reported more hypopigmentation but greater uniformity and effacement of wrinkles with the CO₂ laser.³⁸

Patient selection

Realistic expectations and adherence to pre- and postprocedure regimens are crucial characteristics for any resurfacing procedure. A psychological profile that can endure a long healing period is required for deep chemical peels. Patients usually need a supportive supervisor to assist with hygiene, medications, and feeding in the first days postprocedure. Patients with Fitzpatrick skin phototypes IV to VI are rarely candidates for deep peels because they typically do not suffer evident photoaging and are at risk for pigmentary complications.

Fibrotic, oily skin, such as phymatous rosacea skin,³⁹ may retard the chemical action of the preparation.³² Facial skin may be pretreated with topical retinoids or alpha-hydroxy acids for >1 month to counteract this effect.³² Some patients with thick, oily facial skin may benefit from a course

of isotretinoin that is discontinued ≥1 month before the procedure. A history of malnutrition or poor facial wound healing are contraindications to deep facial peeling. Based on the available literature, deep peels are not recommended in the setting of concurrent systemic isotretinoin, similar to mechanical dermabrasion and fully ablative lasers.⁴⁰ Smoking impairs healing, and some authors recommend tobacco cessation ≥1 year before the procedure.³²

Based on patient history, the appropriate antibacterial, antiviral, and yeast prophylaxis should be instituted. Typically, all patients receive herpes prophylaxis (valacyclovir 500 mg 3 times/day for 7-10 days).

APPLICATION TECHNIQUE

Key points

- **Cardiac monitoring is required for full-face deep peels**
- **The therapeutic effect is increased with more strokes, volume, pressure, and concentration of croton oil**
- **Waiting 10 to 15 minutes between each cosmetic unit minimizes cardiotoxicity**
- **Petrolatum jelly or tape can be used for occlusion**

The first step is to mix croton oil with 88% phenol into a solution, followed by the addition of soap and water (Table III). This preparation separates after 1 minute into 2 phases (Supplementary Video 1, available online at <https://www.jaad.org>).

The face comprises 6 cosmetic units: forehead, periocular, nose, left cheek, right cheek, and perioral area. Marking cosmetic units is helpful when performing segmental peels in which areas to be treated with heavy formulas are clearly differentiated

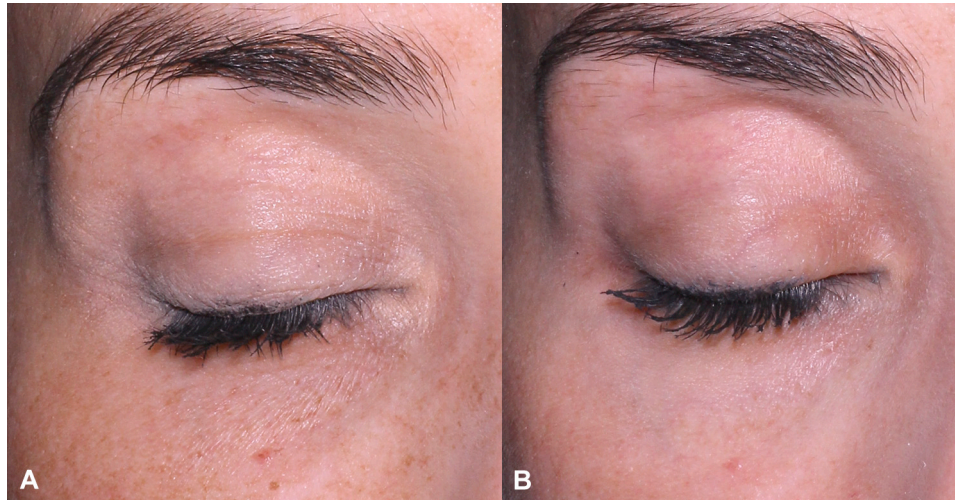


Fig 3. Blepharopeeling with 0.1% croton oil in 35% phenol. **A**, Before: mild static wrinkles, mild laxity, and diffuse melanosis. **B**, After 6 months: effacement of wrinkles, eyelid tightening, and general improvement in skin pigmentation.

from areas to be treated with lighter formulas or medium-depth peels.

Intravenous fluids and analgesia

When conducting full-face peels, intravenous fluids should be administered throughout the procedure to reduce cardiac complications related to phenol toxicity.⁴¹

For segmental peels in which only 1 cosmetic unit is treated, patients are instructed to drink a minimum of 1 L of fluids, such as isotonic sports drinks, or water throughout the procedure.

Numerous variations on pre-, intra-, and postoperative analgesia can be used, including opioids, nonsteroidal antiinflammatory drugs, and benzodiazepines. In addition, regional nerve blocks may be used to enhance comfort. The critical period of discomfort usually occurs about 1 to 4 hours after the peel and lasts until full edema is reached (8 hours).

Application

Washing the skin thoroughly with soap and water followed by acetone is of paramount importance. Lipids, make-up, and other particles prevent penetration of the phenol-croton oil ingredients. After the skin is thoroughly cleansed, application begins. The optimal application technique includes the correct amount of liquid, passes, and pressure.^{16,17} The applicator is rubbed while the other hand stabilizes the skin with a gauze pad for immediate drying of inadvertent drips (Supplementary Video 2, available online at <https://www.jaad.org>). Many physicians prefer cotton-tipped applicators because of the ability to

have fine control. Some use both cotton-tipped applicators and a folded gauze.

The peel solution is feathered into the anterior hairline and scalp. For deep rhytides or a severe scar, the solution can be rubbed aggressively or etched into the area with a cotton-tipped wooden applicator or thin brush to increase penetration.⁴² Initially, an immediate, solid white frost is observed after application; however, the endpoint for a heavy phenol-croton oil peel is a fine gray cast over the skin, which appears after additional peel layers are applied. With increased pressure over deep wrinkles, mild purpura is observed after the frosting subsides and is usually followed by vesiculation over the next hour.

Blepharopeeling reduces excess eyelid laxity and wrinkles (Fig 3).^{32,43-45} When using chemical peels alone, a deeper peel is done in the area that would be surgically excised by upper eyelid blepharoplasty.⁴⁴ A combination of chemical peeling and snip excisions may provide additional retraction.⁴⁵

After completion of the deep peel, occlusion with ointments or tape is typical, although there are no comparative studies in humans to favor one over another in the current literature.^{13,41,46} Petrolatum jelly is noncomedogenic.⁴⁷ Repeated application every 2 to 6 hours provides adequate occlusion, protects against irritants,⁴⁶ prevents fissures, and facilitates eating and mouth hygiene.

When tape is used, a waterproof zinc oxide tape is frequently used. Strips are applied parallel to the anterior hairline to the entire face except the eyes and mouth. This mask is removed by the physician after 24 to 48 hours. Bismuth subgallate powder is frequently applied after tape removal.⁴²

Intraoperative safety

Cardiac safety is a concern for procedures involving >1 cosmetic unit, or >0.5% of the body surface area (equal to a palm without fingers). Air circulation and safety pauses of 10 to 15 minutes between each cosmetic unit of the face (forehead, perioral, periocular, nose, and each cheek) are recommended to allow phenol to be excreted regardless of the number of cosmetic units peeled. A full-face peel should be completed over at least 60 to 90 minutes, with adequate pauses between each cosmetic unit. For peels exceeding 1% of the body surface area, hydration (oral or intravenous), continuous electrocardiographic monitoring, and ventilation/exhaustion of room air are recommended.

Phenol may penetrate regular latex and nitrile gloves. Neoprene gloves are recommended for personal protection,⁴⁸ especially when using gauze pads as applicators. The use of facial masks with activated carbon is recommended for the operating room personnel.^{49,50}

ADVERSE EFFECTS

Key points

- **Seven percent of patients will exhibit transient intraoperative cardiac arrhythmias**
- **Prolonged erythema is an expected side effect**

Transient rate-corrected QT interval prolongation may occur during phenol-croton oil peels⁵¹; therefore, a baseline electrocardiogram is needed for full-face peeling, and drugs known to prolong the rate-corrected QT interval should be discontinued. Approximately 7% of patients undergoing full-face peels will exhibit transient intraoperative cardiac arrhythmias, which are more common in patients who are taking medications known to prolong the rate-corrected QT interval, such as antihypertensive and antidepressant medications.^{42,52} Hemodynamic instability caused by cardiac complications is rare, especially if peels are performed over a long period of time and with appropriate precautions.⁵² There are no reports of cardiac arrest in the literature to date. The rate-corrected QT interval prolongation associated with phenol-croton oil peels typically resolves within 15 minutes of completion of the procedure.⁵¹ Atrial extrasystolic beats and premature ventricular beats are an early warning signal: if these occur, longer pauses are taken, the treatment area is reduced before each pause, air circulation is rechecked, and intravenous fluid delivery is increased. Arrhythmic events may be controlled with an intravenous bolus of ≤ 5 mL of 2% lidocaine

(1-1.5 mg/kg).^{52,53} We recommend using short-acting beta-blockers, such as esmolol or propranolol, prophylactically to reduce the risk of arrhythmia⁵² in patients without contraindications, such as chronic obstructive pulmonary disease, asthma, severe bradycardia, and advanced atrioventricular blocks.

Hypertrophic scar formation may occur in particular areas, such as the zygomatic arch, preauricular area, medial upper eyelids, lateral lower eyelids, and neck, which should consequently be peeled less vigorously. For extremely lax lower eyelids (compromised snap-back test), or previous ectropion, it is prudent to peel this area with a more superficial agent.³² Ectropion resulting from the peel may self-resolve.

Eye irritation with chemosis may be caused by intraoperative exposure to wounding agents, fumes, or intermixing of the patient's tears with the formula. For safety, the eyes should remain shut with an assistant drying the patient's tears throughout the procedure. Cotton-tipped applicators or gauze impregnated with peel solution should never be passed directly over a patient's eyes to avoid accidental dripping. Because opiates decrease tearing by anticholinergic effects, there may be additional benefit for intraoperative narcotics.^{54,55}

Infections are rare. Any systemic sign of increased edema, exudate, odor, or excessive discomfort/pain after the first 48 hours requires antibiotic coverage for *Staphylococcus aureus* and *Pseudomonas aeruginosa*. A single case of toxic shock syndrome was reported in 3 journals.⁵⁶⁻⁵⁸

Postinflammatory hyperpigmentation usually lasts <6 months and may be followed by pseudohypopigmentation, where the skin color is actually normal but appears hypopigmented compared with untreated, sun-damaged skin (Fig 4). Feathering may avoid demarcation lines, and some physicians prefer segmental treatment for more adequate color matching. Even patients with lighter Fitzpatrick skin phototypes may require segmental treatments for uniform color results (Fig 5).

Leukoderma may occur from subepidermal fibrosis, even though melanocytes are still present.²⁶

Prolonged erythema starts during the first week and peaks in the second week postprocedure. Erythema is a normal part of the healing process and is a surrogate sign of reticular dermal collagen formation. The patient must be forewarned of its benign nature. Patients are normally erythematous for 3 to 6 months and with exercise for as long as a year. The peel depth and long-term effectiveness are directly proportional to the degree and duration of

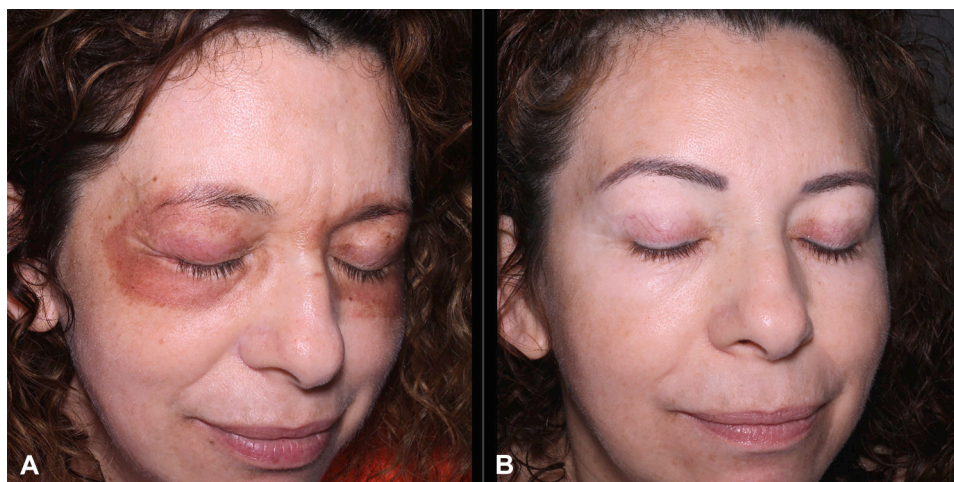


Fig 4. Postinflammatory hyperpigmentation after a periocular 1.2% croton oil in 35% phenol peel. **A**, Persistent postinflammatory hyperpigmentation is notable in the periocular region. **B**, At 2 years' follow-up, pseudohypopigmentation is evident in the periocular area compared with the sun-damaged skin of the temples and cheeks. Peeling the sun-damaged areas will minimize the color discrepancy.

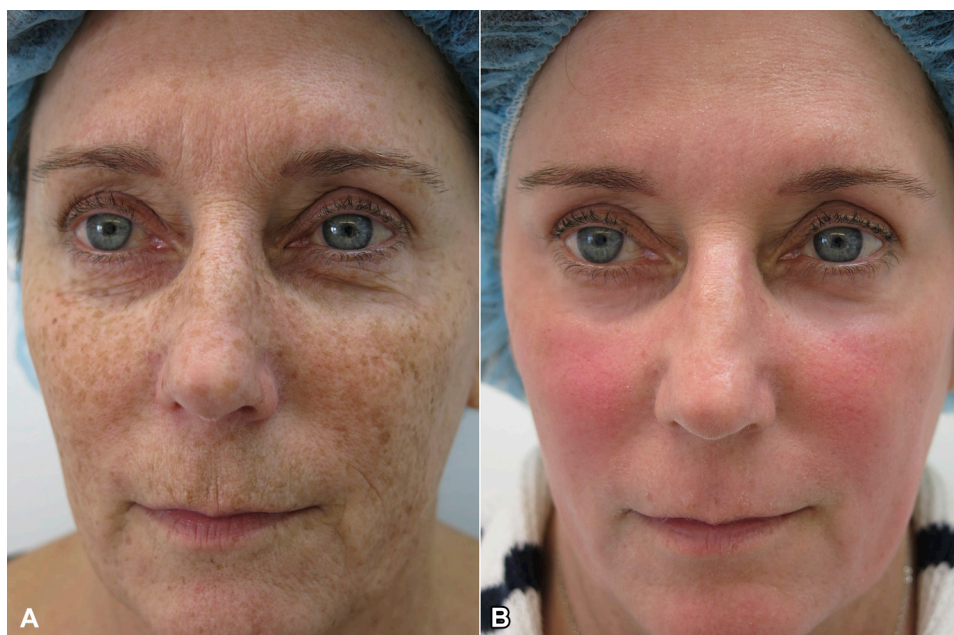

Fig 5. Segmental peeling with 1.1% croton oil in 33% phenol (perioral and glabella), 0.35% croton oil in 33% phenol (eyelids, temples, and cheeks), combined with Jessner solution followed by 35% trichloroacetic acid over the forehead where less severe photoaging was present. **A**, Before and **(B)** after 5 months of follow-up.

the erythema.¹⁶ During the erythematous phase, the skin is usually dry and more sensitive to irritation and flushing.

In conclusion, phenol-croton oil peeling effects have greater longevity than many other resurfacing procedures.^{20,24} Croton oil is a rich and complex compound containing phorbol esters. Varying the concentration of croton oil in phenol enables

tailoring of appropriate formulas to the degree of sun-damage requiring treatment. Successful outcomes depend on a balance of art and technique, patient education, and safety standards. The cost-effectiveness of deep chemical peeling compared with other resurfacing methods is superlative. Supervised hands-on training is irreplaceable, either in training programs or in

continuing medical education. The International Peeling Society offers several workshops throughout the year.

We thank Gregory Hetter, MD, for the generosity of his time and expertise with making revisions to this article. We thank the scientists of the Laboratory of Phytotherapy, Phytotherapy Technology and Chemistry of Natural Products at the State University of Ponta Grossa—Flávio Beltrame, PharmD, PhD, for reviewing this article and Aline da Silva Justo, PharmD, MSc, and Bruna Mikulis Lemes, PharmD, MSc, for generously providing photomicrographs of their research. We also thank the reviewers and the members of the International Peeling Society for their diligence in compiling and reviewing this article.

REFERENCES

1. Wambier CG, Lee KC, Bertolini TM, Rullan PP, Beltrame FL. Comment on "Anti-aging effects of ingenol mebutate for patients with actinic keratosis" and phenol-croton oil peelings. *J Am Acad Dermatol*. 2019;80:e185-e186.
2. Bertolini TM. Is the phenol-croton oil peel safe? *Plast Reconstr Surg*. 2002;110:715-717.
3. Hutchinson R. Observations on the employment of croton oil. *Lancet*. 1833;20:229-231.
4. Hetter GP. An examination of the phenol-croton oil peel: part II. The lay peelers and their croton oil formulas. *Plast Reconstr Surg*. 2000;105:240-248.
5. Larson DL, Karmo F, Hetter GP. Phenol-croton oil peel: establishing an animal model for scientific investigation. *Aesthet Surg J*. 2009;29:47-53.
6. Brown AM. Skin treating method and composition. In: U. S. P. Office, ed. US: Mount Sinai Hospital Corp; Foundation for Prosthetic Research; 1959:3.
7. Litton C. Chemical face lifting. *Plast Reconstr Surg Transplant Bull*. 1962;29:371-380.
8. Baker TJ. The ablation of rhytides by chemical means. A preliminary report. *J Fla Med Assoc*. 1961;48:451-454.
9. Wambier CG, Brody HJ, Hetter GP. Comments: hemiface comparative study of two phenol peels (Baker-Gordon and Hetter formulas) for the correction of facial rhytids. *Surg Cosmet Dermatol*. 2017;9:190-191.
10. Baker TJ. Chemical face peeling and rhytidectomy. A combined approach for facial rejuvenation. *Plast Reconstr Surg Transplant Bull*. 1962;29:199-207.
11. Hetter GP. An examination of the phenol-croton oil peel: part III. The plastic surgeons' role. *Plast Reconstr Surg*. 2000;105:752-763.
12. Neitzke I, Curi D, Wambier C. Randomized controlled trial on the use of Septisol and Johnson's baby shampoo in a phenol-croton oil peel formula. Available at: http://www.ensaioclinicos.gov.br/static/attachments/pb_parecer_consustanciado_cep_279_6366_1.pdf. Accessed April 14, 2019.
13. Hetter GP. An examination of the phenol-croton oil peel: part IV. Face peel results with different concentrations of phenol and croton oil. *Plast Reconstr Surg*. 2000;105:1061-1083.
14. Hetter GP. An examination of the phenol-croton oil peel: part I. Dissecting the formula. *Plast Reconstr Surg*. 2000;105:227-239.
15. Baker TJ, Stuzin JM. An examination of the phenol-croton oil peel: part IV. Face peel results with different concentrations of phenol and croton oil by Gregory P. Hetter, MD. *Plast Reconstr Surg*. 2000;105:1084-1087.
16. Larson DL. Phenol-croton oil peel: an update. *Aesthet Surg J*. 2005;25:197-200.
17. Stone PA, Lefer LG. Modified phenol chemical face peels: recognizing the role of application technique. *Clin Plast Surg*. 2001;28:13-36.
18. Bensimon RH. Croton oil peels. *Aesthet Surg J*. 2008;28:33-45.
19. Behin F, Feuerstein SS, Marovitz WF. Comparative histological study of mini pig skin after chemical peel and dermabrasion. *Arch Otolaryngol*. 1977;103:271-277.
20. Kligman AM, Baker TJ, Gordon HL. Long-term histologic follow-up of phenol face peels. *Plast Reconstr Surg*. 1985;75:652-659.
21. Giese SY, McKinney P, Roth SI, Zukowski M. The effect of chemosurgical peels and dermabrasion on dermal elastic tissue. *Plast Reconstr Surg*. 1997;100:489-498.
22. Fitzpatrick RE, Tope WD, Goldman MP, Satur NM. Pulsed carbon dioxide laser, trichloroacetic acid, Baker-Gordon phenol, and dermabrasion: a comparative clinical and histologic study of cutaneous resurfacing in a porcine model. *Arch Dermatol*. 1996;132:469-471.
23. Stegman SJ. A comparative histologic study of the effects of three peeling agents and dermabrasion on normal and sun-damaged skin. *Aesthetic Plast Surg*. 1982;6:123-135.
24. Baker TJ, Gordon HL, Mosienko P, Seckinger DL. Long-term histological study of skin after chemical face peeling. *Plast Reconstr Surg*. 1974;53:522-525.
25. Baker TJ, Gordon HL. Chemical face peeling and dermabrasion. *Surg Clin North Am*. 1971;51:387-401.
26. Baker TJ, Gordon HL, Seckinger DL. A second look at chemical face peeling. *Plast Reconstr Surg*. 1966;37:487-493.
27. Spira M, Dahl C, Freeman R, Gerow FJ, Hardy SB. Chemosurgery—a histological study. *Plast Reconstr Surg*. 1970;45:247-253.
28. Stegman SJ. A study of dermabrasion and chemical peels in an animal model. *J Dermatol Surg Oncol*. 1980;6:490-497.
29. Moy LS, Kotler R, Lesser T. The histologic evaluation of pulsed carbon dioxide laser resurfacing versus phenol chemical peels in vivo. *Dermatol Surg*. 1999;25:597-600.
30. Zukowski ML, Mossie RD, Roth SI, Giese S, McKinney P. Pilot study analysis of the histologic and bacteriologic effects of occlusive dressings in chemosurgical peel using a minipig model. *Aesthetic Plast Surg*. 1993;17:53-59.
31. Fintsi Y. Exoderm—a novel, phenol-based peeling method resulting in improved safety. *Am J Cosm Surg*. 1997;14:49-54.
32. Wambier CG, de Freitas FP. Combining phenol-croton oil peel. In: Issa MCA, Tamura B, eds. *Chemical and Physical Procedures*. Cham, Switzerland: Springer International Publishing; 2017:1-13.
33. Wambier CG, Neitzke IC, Lee KC, et al. Augmentation and eversion of lips without injections: the lip peel. *J Am Acad Dermatol*. 2019;80(5):e119-e120.
34. Wambier CG, Paschoal RS, Forno TD, Lee KC. Survey on the efficacy, costs and healing of resurfacing procedures for facial static wrinkles. *Surg Cosmet Dermatology*. 2018;10(4):365-367.
35. Brody HJ. Do chemical peels tighten the skin? *Dermatol Surg*. 2014;40(suppl 12):S129-S133.
36. Chew J, Gin I, Rau KA, Amos DB, Bridenstine JB. Treatment of upper lip wrinkles: a comparison of 950 microsec dwell time carbon dioxide laser with unoccluded Baker's phenol chemical peel. *Dermatol Surg*. 1999;25:262-266.
37. Vasconcelos B, Figueira G, Fonseca J, Mendonça L, Fonseca C. A splitface comparative study between two phenol-based peelings (Baker-Gordon and Hetter formulas) in the treatment of facial rhytids. *Surg Cosmet Dermatol*. 2013;5:40-44.
38. Langsdon PR, Milburn M, Yarber R. Comparison of the laser and phenol chemical peel in facial skin resurfacing. *Arch Otolaryngol Head Neck Surg*. 2000;126:1195-1199.

39. Schuurmann M, Wetzig T, Wickenhauser C, Ziepert M, Kreuz M, Ziemer M. Histopathology of rhinophyma—a clinical-histopathologic correlation. *J Cutan Pathol*. 2015;42:527-535.
40. Spring LK, Krakowski AC, Alam M, et al. Isotretinoin and timing of procedural interventions: a systematic review with consensus recommendations. *JAMA Dermatol*. 2017;153:802-809.
41. Beeson WH, McCollough EG. Chemical face peeling without taping. *J Dermatol Surg Oncol*. 1985;11:985-990.
42. Rullan PP, Lemon J, Rullan J. The 2-day light phenol chemabrasion for deep wrinkles and acne scars: a presentation of face and neck peels. *Am J Cosm Surg*. 2004;21:199-210.
43. Orra S, Waltzman JT, Mlynek K, Duraes EFR, Kundu N, Zins JE. Periorbital phenol-croton oil chemical peel in conjunction with blepharoplasty: an evolving technique for periorbital facial rejuvenation. *Plast Reconstr Surg*. 2015;136:99-100.
44. Parada MB, Yarak S, Gouvea LG, Hassun KM, Talarico S, Bagatin E. “Blepharopeeling” in the upper eyelids: a nonincisional procedure in periorbital rejuvenation—a pilot study. *Dermatol Surg*. 2008;34:1435-1438.
45. Sterling JB. Micropunch blepharopeeling of the upper eyelids: a combination approach for periorbital rejuvenation—a pilot study. *Dermatol Surg*. 2014;40:436-440.
46. Stuzin JM, Baker TJ, Gordon HL. Chemical peel: a change in the routine. *Ann Plast Surg*. 1989;23:166-169.
47. Kligman AM. Petrolatum is not comedogenic in rabbits or humans: a critical reappraisal of the rabbit ear assay and the concept of “acne cosmetica.”. *J Cosmet Sci*. 1996;47:41-48.
48. Shelley T. *Hand protection and glove selection. Including glove selection for some specific chemicals*. Ithaca, NY: Cornell Environmental Health and Safety; 1999. Available at: <https://www.yumpu.com/en/document/read/38575586/hand-protection-and-glove-selection-cornell-university>. Accessed April 7, 2019.
49. Wambier CG, Beltrame FL. Air safety and personal protective equipment for phenol-croton oil peels. *Dermatol Surg*. 2018;44:1035-1037.
50. Wambier CG, Lee KC, Oliveira PB de, Wambier SP de F, Beltrame FL. Comment on “Surgical smoke: Risk assessment and mitigation strategies” and chemical adsorption by activated carbon N95 masks. *J Am Acad Dermatol*. 2019;80(4):e79-e80.
51. Wambier CG, Wambier SPDF, Pilatti LEP, Grabicoski JA, Wambier LF, Schmidt A. Prolongation of rate-corrected QT interval during phenol-croton oil peels. *J Am Acad Dermatol*. 2018;78:810-812.
52. Landau M. Cardiac complications in deep chemical peels. *Dermatol Surg*. 2007;33:190-193.
53. Botta SA, Straith RE, Goodwin HH. Cardiac arrhythmias in phenol face peeling: a suggested protocol for prevention. *Aesthetic Plast Surg*. 1988;12:115-117.
54. Margas W, Mahmoud S, Ruiz-Velasco V. Muscarinic acetylcholine receptor modulation of mu (μ) opioid receptors in adult rat sphenopalatine ganglion neurons. *J Neurophysiol*. 2010;103:172-182.
55. Zagon IS, Klocek MS, Sassani JW, McLaughlin PJ. Dry eye reversal and corneal sensation restoration with topical naltrexone in diabetes mellitus. *Arch Ophthalmol*. 2009;127:1468-1473.
56. Dmytryshyn JR. Phenol peels and toxic shock syndrome. *J Am Acad Dermatol*. 1983;9:163.
57. Dmytryshyn JR, Gribble MJ, Kassen BO. Chemical face peel complicated by toxic shock syndrome: a case report. *Arch Otolaryngol*. 1983;109:170-171.
58. Korcok M. Untoward effect of a face peel: toxic shock syndrome. *JAMA*. 1982;248:23.